

doi: 10.13241/j.cnki.pmb.2020.07.028

高频超声与喉镜检查对甲状腺癌侵犯喉返神经的术前评价价值分析*

黄靖¹ 吴飞凤² 杨增娣¹ 任明磊¹ 童清平^{1△}

(中国人民解放军联勤保障部队第901医院 1 超声中心; 2 耳鼻咽喉科 安徽 合肥 230031)

摘要 目的:比较高频超声与喉镜检查对甲状腺癌侵犯喉返神经(recurrent laryngeal nerve, RLN)的术前评价价值。**方法:**选择 2012 年 2 月到 2019 年 8 月在本医院进行诊治的甲状腺癌患者 207 例,采用高频超声与喉镜进行术前评估侵犯喉返神经情况,记录超声特征并判断诊断价值(以病理检查作为金标准)。**结果:**在 207 例甲状腺癌患者中,术后病理学证实喉返神经侵犯 52 例(侵犯组),转移率为 25.1%。侵犯组的性别、年龄、发病位置、体重指数、病程等与非侵犯组患者对比差异无统计学意义($P>0.05$)。侵犯组超声显示病灶形态、内部回声、边界、钙化、晕环等特征与非侵犯组对比差异有统计学意义($P<0.05$),主要表现为侵犯组的病灶形态不规则、无晕环、无钙化、边界不清晰、内部高超声均显著高于非侵犯组($P>0.05$)。侵犯组的峰值强度(Peak intensity, PI)值高于非侵犯组患者($P<0.05$),两组达峰时间(Peak time, TP)与 AUC 值对比差异无统计学意义($P>0.05$)。在 207 例患者中,高频超声判断为喉返神经侵犯 43 例,喉镜判断为喉返神经侵犯 39 例,高频超声与喉镜检查对甲状腺癌侵犯喉返神经的术前诊断敏感性为 97.7% 和 97.4%,特异性为 93.9% 和 91.7%,高频超声诊断的敏感性和特异性比喉镜检查稍优。ROC 曲线显示高频超声诊断的 AUC 为 0.903,喉镜检查的 AUC 为 0.860。**结论:**高频超声与喉镜检查对甲状腺癌侵犯喉返神经的术前评价的应用价值相当,均有很高的敏感性与特异性,能准确反映患者侵犯喉返神经的情况。

关键词:高频超声;喉镜;甲状腺癌;侵犯喉返神经;超声造影

中图分类号:R736.1 文献标识码:A 文章编号:1673-6273(2020)07-1331-04

Analysis of the Preoperative Evaluation Values of High Frequency Ultrasound and Laryngoscopy for the Thyroid Cancer Invasion of Recurrent Laryngeal Nerve*

HUANG Jing¹, WU Fei-feng², YANG Zeng-di¹, REN Ming-lei¹, TONG Qing-ping^{1△}

(1 Ultrasound Center; 2 Department of Otolaryngology, The 901st Hospital of the People's Liberation Army Joint Service Support Force Hefei, Anhui, 230031, China)

ABSTRACT Objective: Comparison of the preoperative evaluation values of high frequency ultrasound and laryngoscopy for the thyroid cancer invasion of recurrent laryngeal nerve (RLN). **Methods:** A total of 207 patients with the thyroid cancer who were treated in our hospital from February 2012 to August 2019 were selected. The high-frequency ultrasound and laryngoscopy were used to evaluate the preoperative RLN before surgery. The characteristics of the ultrasound were recorded and the diagnostic values were judged (Pathological examination as the gold standard). **Results:** There were 52 patients of RLN invasion (invasion group) by the postoperative pathology in the 207 cases that the metastatic rate of 25.1%. There were no significant differences in gender, age, location, body mass index, and duration of disease compared between the invasive group and the non-invasive group ($P>0.05$). Ultrasound showed that the lesion morphology, halo, calcification, border, internal echo and other features were significantly different compared between the non-invasive group and the non-invasive group ($P<0.05$). It was mainly characterized by irregular lesion shapes, no halo, no Calcification, unclear borders, and internal ultrasonography were significantly higher than the non-invasive group ($P>0.05$). The peak intensity (PI) value of the invasion group was higher than that of the non-invasive group ($P<0.05$), and there were no significant difference in peak time (TP) and AUC values compared between the two groups ($P>0.05$). In the 207 patients, high-frequency ultrasound were judged as 43 cases of recurrent laryngeal nerve invasion, and laryngoscopy confirmed 39 cases of recurrent laryngeal nerve invasion. The preoperative diagnostic sensitivity of high-frequency ultrasound and laryngoscopy for thyroid cancer invasion of the recurrent laryngeal nerve was 97.7% and 97.4%, and the specificity was 93.9% and 91.7%. High-frequency ultrasound has slightly better sensitivity and specificity than laryngoscopy. The ROC curve shows that the AUC of the high-frequency ultrasound diagnosis is 0.903, and the AUC of the laryngoscopy is 0.860. **Conclusion:** High-frequency ultrasound and laryngoscopy are of equal value in the preoperative evaluation of thyroid cancer inva-

* 基金项目:安徽省军区科研面上项目(MS046)

作者简介:黄靖(1987-),女,本科,医师,研究方向:超声临床诊断,电话:18297993207, E-mail:huangjing182979@163.com

△ 通讯作者:童清平(1965-),硕士,主任医师,研究方向:超声临床诊断,电话:18909696268, E-mail:tongqp168@163.com

(收稿日期:2019-09-02 接受日期:2019-09-26)

sion of the recurrent laryngeal nerve, which have high sensitivity and specificity and can accurately reflect the patient's recurrent laryngeal nerve invasion.

Key words: High frequency ultrasound; Laryngoscope; Thyroid cancer; Invasion of recurrent laryngeal nerve; Contrast-enhanced ultrasound

Chinese Library Classification(CLC): R736.1 **Document code:** A

Article ID: 1673-6273(2020)07-1331-04

前言

手术是目前甲状腺癌治疗的最有效方法,能有效延长患者的生存时间^[1,2]。但在根治手术中,癌肿的患侧甲状腺腺叶需完整切除,也需要行不同程度的颈部淋巴结清扫术,这增加了喉返神经(recurrent laryngeal nerve, RLN)损伤的几率^[3,4]。喉返神经侵犯当前被定义为肿瘤细胞进入、包绕或穿透喉返神经组织,在甲状腺癌中的发生率比较高,为此术中进行喉返神经保护是甲状腺癌手术操作的重点^[5]。喉返神经 RLN 与甲状腺特殊的位置关系、喉返神经变异的多样性,贴近后包膜的或肿瘤靠近中上极的更有可能侵犯神经^[6,7]。术前准确评价甲状腺癌侵犯喉返神经情况有助于外科医师选择正确的手术方式^[8]。

临床上常规诊断喉返神经侵犯的方法为喉镜检查,虽然准确率较高,但具有一定侵入性与创伤性^[9]。超声是甲状腺癌诊断最简便有效的影像学检查方法,常规的超声检查虽然有助于甲状腺癌喉返神经侵犯的鉴别诊断,但是存在一定的假阳性与假阴性^[10,11]。超声造影(CEUS, Contrast enhanced ultrasound)是将微泡造影剂经外周静脉注射后到达靶器官或靶组织,通过增强后散射、改变声衰减等原理,提高超声诊断的准确性^[12-14]。本研究具体探讨与分析了高频超声与喉镜检查对甲状腺癌侵犯喉返神经的术前评价价值,现总结报道如下。

1 资料与方法

1.1 研究对象

选择 2012 年 2 月到 2019 年 8 月在本院进行诊治的甲状腺癌患者 207 例,纳入标准:穿刺或手术病理检查证实为甲状腺癌;有完善的临床资料;单侧发病;组织病理学检测结果完整;全部行手术治疗,手术包括中央区淋巴结清扫术,部分包括颈侧区淋巴结清扫术。排除标准:手术禁忌症患者;临床资料缺乏者;因甲状软骨钙化或喉结前凸遮挡导致声带结构和运动显示不清者。本研究通过医院伦理委员会批准与所有患者及家属的知情同意。

1.2 高频超声方法

使用西门子 SIMENS(Acuson Sequoia 512)高频线阵探头 15L8 W(7.5-10 MHz)和日立 HITACHI 高频彩超诊断仪(Hi Vision AVI-US),配套 9L4 线阵探头,频率 5-9 MHz。患者取仰卧位,垫高颈部,充分暴露颈部,超声记录病灶形态、内部回声、边界、钙化、晕环等情况。采用第二代超声微泡造影剂 SonoVue (意大利 Bracco 公司,主要成分为六氟化硫微泡),嘱患者平静呼吸后启动造影模式,经肘静脉快速团注 SonoVue 混悬液 1.2 mL,继之快速推注 0.9% 的氯化钠溶液 5 mL,持续观察并动态储存造影图像。造影参数:机械指数 0.07,增益 30%;绘制时间-强度图,记录造影剂的相关指标等。感兴趣区域(region of interest, ROI) 为整个病灶。记录峰值强度 (Peak intensity, PI, %)、AUC 曲线下面积(1/s)、达峰时间(Peak time, TP, ms, 病灶内出现第一个造影剂微泡至到达灌注峰值的时间)。

1.3 喉镜检查

超声检查后进行常规喉镜检查,由不知超声检查结果的同一名喉镜医师检测。同时所有患者进行病理检查,以病理检查结果作为金标准。

1.4 统计学分析

选择 SPSS19.00 软件进行数据分析,计数数据以百分比表示,组间对比行 χ^2 检验,计量数据以均数 \pm 标准差表示,组间对比为 t 检验,以病理检查结果为金标准,判断诊断价值,以 $P < 0.05$ 为差异显著。

2 结果

2.1 甲状腺癌术后侵犯喉返神经的发生情况

在 207 例甲状腺癌患者中,术后病理学证实喉返神经侵犯 52 例(侵犯组),转移率为 25.1%。

2.2 甲状腺癌术后喉返神经侵犯组与未侵犯组患者的一般资料对比

侵犯组患者的性别、年龄、发病位置、体重指数、病程等与非侵犯组患者对比差异无统计学意义($P > 0.05$)。见表 1。

表 1 甲状腺癌术后喉返神经侵犯组与未侵犯组患者的一般资料对比

Table 1 Comparison of the general data between invasive group and non-invasive group

Groups	n	Gender (Male/ Female)	Age (olds)	Incidence location (left/right)	BMI (kg/m ²)	Course of disease (years)	Maximum tumor diameter (cm)
Invasive group	52	32/30	51.01 \pm 3.10	26/26	22.59 \pm 2.18	2.92 \pm 0.56	4.44 \pm 0.09
Non-invasive group	155	80/75	50.28 \pm 2.48	78/77	22.19 \pm 1.98	2.98 \pm 0.66	1.52 \pm 0.11

2.3 甲状腺癌术后喉返神经侵犯组与未侵犯组患者的常规超声特征对比

侵犯组超声显示病灶形态、内部回声、边界、钙化、晕环等特征与非侵犯组对比差异有统计学意义($P < 0.05$),主要表现为

侵犯组的病灶形态不规则、无晕环、无钙化、边界不清晰、内部高超声均显著高于非侵犯组($P < 0.05$)。见表 2。

2.4 甲状腺癌术后喉返神经侵犯组与未侵犯组患者的超声造影指标对比

侵犯组的 PI 值高于非侵犯组患者($P<0.05$),两组 TP 与 AUC 值 对比差异无统计学意义($P>0.05$)。见表 3。

表 2 甲状腺癌术后喉返神经侵犯组与未侵犯组患者的常规超声特征对比(例,%)

Table 2 Comparison of the conventional ultrasound features between invasive group and non-invasive group (n,%)

Groups	n	Form (rule / irregular)	Halo (with/without)	Calcification (with/without)	Boundary (clear/unclear)	Internal echo (low / equal / high)
Invasive group	52	2/50*	7/45*	2/50*	12/40*	6/6/40*
Non-invasive group	155	132/20	145/10	142/13	132/20	120/25/10

Note: Compare with the Invasive group, * $P<0.05$.

表 3 甲状腺癌术后喉返神经侵犯组与未侵犯组患者的超声造影指标对比

Table 3 Comparison of the contrast-enhanced ultrasound indicators between invasive group and non-invasive group

Groups	n	TP (ms)	AUC (1/s)	PI (%)
Invasive group	52	23782± 4561	6.09± 0.45	24.69± 2.51*
Non-invasive group	155	24209± 5119	5.97± 2.00	20.41± 5.20

表 4 高频超声与喉镜检查对甲状腺癌侵犯喉返神经的术前诊断价值

Table 4 Preoperative diagnosis value of high frequency ultrasound and laryngoscopy for thyroid cancer invasion of recurrent laryngeal nerve

Pathology	High frequency ultrasound		Laryngoscope		Total
	Recurrent laryngeal nerve invasion	Non-recurrent laryngeal nerve invasion	Recurrent laryngeal nerve invasion	Non-recurrent laryngeal nerve invasion	
Recurrent laryngeal nerve invasion	42	10	38	14	52
Non-recurrent laryngeal nerve invasion	1	154	1	154	155
Total	43	164	39	168	207

2.5 高频超声与喉镜检查对甲状腺癌侵犯喉返神经的术前诊断价值

在 207 例患者中,高频超声判断为喉返神经侵犯 43 例,喉镜判断为喉返神经侵犯 39 例,高频超声与喉镜检查对甲状腺癌侵犯喉返神经的术前诊断敏感性为 97.7%和 97.4%,特异性为 93.9%和 91.7%,高频超声诊断的敏感性和特异性比喉镜检查稍优。见表 4。ROC 曲线显示高频超声诊断的 AUC 为 0.903,喉镜检查的 AUC 为 0.860,见图 1。

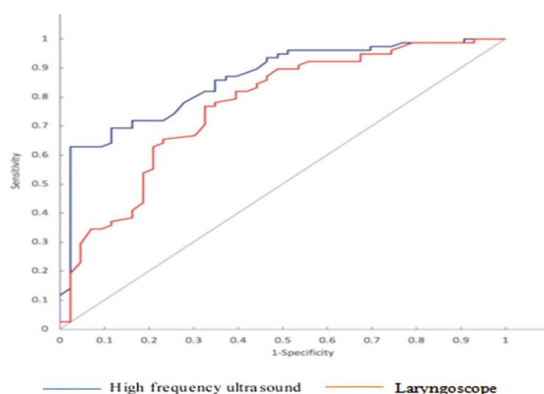


图 1 高频超声与喉镜检查对甲状腺癌侵犯喉返神经的术前诊断的 ROC 曲线

Fig.1 ROC curve of preoperative diagnosis of thyroid cancer invasion of the recurrent laryngeal nerve by high-frequency ultrasound and laryngoscopy

3 讨论

甲状腺癌为临床上常见的恶性肿瘤,但是预后相对比较好,术后 10 年的生存率为 70%^[15]。但当患者被诊断为喉返神经侵犯时,预后变差,死亡风险也因此增加^[16]。当前有研究对肿瘤侵犯神经进行了量化定义,即肿瘤贴近神经并包绕 $\geq 1/3$ 神经周径或肿瘤细胞穿透神经鞘 3 层中的任意一层^[17]。有研究显示分化型甲状腺癌的被喉返神经侵犯的发病率为 5%-40%,使肿瘤复发率及病死率增加 2 倍以上^[18],且甲状腺癌的喉返神经侵犯直接影响临床分期和手术方案,使得手术中不完全切除甲状腺的风险增加^[19-21]。本研究显示在 207 例甲状腺癌患者中,术后病理学证实喉返神经侵犯 52 例(侵犯组),转移率为 25.1%,可能与本研究中收治的中晚期甲状腺癌患者比较多等有关。

目前,临床最常用的进行甲状腺癌术前评价方法是直接喉镜检查观察声带活动以评价喉返神经功能,但部分患者无法耐受喉镜这种侵入性检查^[22,23]。此外,部分患者存在声带过度内收或声门前后径缩短的解剖特点,导致喉镜对喉内结构观察困难。对于甲状腺癌患者而言,超声是术前的常规检查,具有重复性好、无创、快捷等优点^[24],除了直接对喉返神经情况进行评估外,一些超声特征可能是甲状腺癌喉返神经侵犯的危险因素^[25]。本研究中,侵犯组超声显示病灶形态、内部回声、边界、钙化、晕环等特征与非侵犯组对比有差异,主要表现为侵犯组的病灶形态不规则、无晕环、无钙化、边界不清晰、内部高回声均显著高于非侵犯组。有研究也显示形态不规则、钙化是甲状腺癌喉返神经

侵犯的有效诊断特征,但是判断的敏感性与特异性有待提高^[29]。特别是当前的高频超声优势在于可清晰显示不同维度的图像,而能够更可靠、更客观地评估伴随甲状腺癌的喉返神经侵犯情况。

超声造影的原理是通过外周静脉注入微泡造影剂,使微泡悬浮于血液中,导致所在部位回声增强,增强了微泡的背向散射,增大血液与气体的声阻抗差,因此能显著增强肿瘤微血管的显示,提高肿瘤的检出率^[27]。由于甲状腺是人体内存血最丰富的器官之一,且良恶性病灶与正常甲状腺实质的血供情况不一,超声造影已被用于甲状腺癌的鉴别诊断^[28]。本研究显示侵犯组患者的PI值高于非侵犯组患者,两组TP与AUC值对比差异无统计学意义。从机制上分析,喉返神经侵犯的甲状腺癌组织,常呈低灌注,并可出现因坏死液化而导致的无灌注区。并且超声造影对被喉返神经侵犯有更高的敏感度和特异度,对手术治疗的术前分期、术式选择及术后管理起到辅助决策作用^[29]。

对于甲状腺癌患者而言,其手术过程的复杂程度高于甲状腺良性疾病患者,术中喉返神经的解剖、保护及功能的保留是手术的重点^[30]。临床上可通过超声内镜在甲状腺附近透过食道进行超声检查,主要用来观察可能有侵犯喉返神经的甲状腺癌患者^[31]。本研究显示高频超声与喉镜检查对甲状腺癌侵犯喉返神经的术前诊断敏感性为97.7%和97.4%,特异性为93.9%和91.7%。ROC曲线显示高频超声诊断的AUC为0.903,喉镜检查的AUC为0.860。说明高频超声甲状腺癌侵犯喉返神经的诊断价值优于喉镜检查,表明高频超声对甲状腺癌侵犯喉返神经术前的诊断是可靠的,能准确反映患者的侵犯喉返神经的情况。

总之,高频超声与喉镜检查对甲状腺癌侵犯喉返神经的术前评价的应用价值相当,均有很高的敏感性与特异性,能准确反映患者侵犯喉返神经的情况。但本研究也有一定的不足,没有纳入甲状腺癌双侧病灶的患者,且样本数量较少,超声的准确性也有待进一步研究证明。

参考文献(References)

- [1] Bian C, Liu H, Yao XY, et al. Complete endoscopic radical resection of thyroid cancer via an oral vestibule approach [J]. *Oncol Lett*, 2018, 16(5): 5599-5606
- [2] Chen C, Huang S, Huang A, et al. Total endoscopic thyroidectomy versus conventional open thyroidectomy in thyroid cancer: a systematic review and meta-analysis [J]. *Ther Clin Risk Manag*, 2018, 14: 2349-2361
- [3] D'orazi V, Sacconi A, Trombetta S, et al. May predictors of difficulty in thyroid surgery increase the incidence of complications? Prospective study with the proposal of a preoperative score [J]. *BMC Surg*, 2019, 18(Suppl 1): 116-124
- [4] Echanique KA, Govindan A, Mohamed OM, et al. Age-Related Trends of Patients Undergoing Thyroidectomy: Analysis of US Inpatient Data from 2005 to 2013 [J]. *Otolaryngol Head Neck Surg*, 2019, 160(3): 457-464
- [5] Haciyanli M. In reference to International neuromonitoring study group guidelines 2018: Part II: Optimal recurrent laryngeal nerve management for invasive thyroid cancer-incorporation of surgical, laryngeal, and neural electrophysiologic data [J]. *Laryngoscope*, 2019, 129(9): E305
- [6] Kim HK, Chai YJ, Dionigi G, et al. Transoral Robotic Thyroidectomy for Papillary Thyroid Carcinoma: Perioperative Outcomes of 100 Consecutive Patients[J]. *World J Surg*, 2019, 43(4): 1038-1046
- [7] Li C, Xiang J, Wang Y. Risk Factors for Predicting Lymph Nodes Posterior to Right Recurrent Laryngeal Nerve (LN-prRLN) Metastasis in Thyroid Papillary Carcinoma: A Meta-Analysis [J]. *Int J Endocrinol*, 2019, 2019: 1-15
- [8] Liu J, Ren J, Lv D, et al. Simultaneous tracheal and esophageal reconstruction for thyroid cancer involving trachea and esophagus using a free bipaddled posterior tibial artery perforator flap [J]. *Head Neck*, 2019, 41(9): 3472-3477
- [9] Liu P, Zhang Y, Qi X, et al. Unilateral Axilla-Bilateral Areola Approach for Thyroidectomy by da Vinci Robot: 500 Cases Treated by the Same Surgeon[J]. *J Cancer*, 2019, 10(16): 3851-3859
- [10] Machens A, Elwerr M, Schneider R, et al. Disease impacts more than age on operative morbidity in children with Graves' disease after total thyroidectomy[J]. *Surgery*, 2018, 164(5): 993-997
- [11] Mizuno K, Takeuchi M, Kanazawa Y, et al. Recurrent laryngeal nerve paralysis after thyroid cancer surgery and intraoperative nerve monitoring[J]. *Laryngoscope*, 2019, 129(8): 1954-1960
- [12] Molteni G, Bonali M, Mattioli F, et al. Central compartment revision surgery for persistent or recurrent thyroid carcinoma: analysis of survival and complication rate[J]. *Eur Arch Otorhinolaryngol*, 2019, 276(2): 551-557
- [13] Onoda N, Noda S, Tauchi Y, et al. Continuous intraoperative neuromonitoring for thyroid cancer surgery: A prospective study [J]. *Laryngoscope Investig Otolaryngol*, 2019, 4(4): 455-459
- [14] Pantvaidya G, Mishra A, Deshmukh A, et al. Does the recurrent laryngeal nerve recover function after initial dysfunction in patients undergoing thyroidectomy? [J]. *Laryngoscope Investig Otolaryngol*, 2018, 3(3): 249-252
- [15] Prete F P, Marzaioli R, Lattarulo S, et al. Transaxillary robotic-assisted thyroid surgery: technique and results of a preliminary experience on the Da Vinci Xi platform[J]. *BMC Surg*, 2019, 18(Suppl 1): 19-30
- [16] Randolph GW, Kamani D. In Response to letter to the editor regarding International Neuromonitoring Study Group Guidelines 2018: Part II: Optimal Recurrent Laryngeal Nerve Management for Invasive Thyroid Cancer-Incorporation of Surgical, Laryngeal, and Neural Electrophysiologic Data[J]. *Laryngoscope*, 2019, 129(9): E306
- [17] Roman BR, Randolph GW, Kamani D. Conventional Thyroidectomy in the Treatment of Primary Thyroid Cancer [J]. *Endocrinol Metab Clin North Am*, 2019, 48(1): 125-141
- [18] Saleh SO, Hojaij FC, Itezeroti AM, et al. Level VI lymph nodes: an anatomic study of lymph nodes located between the recurrent laryngeal nerve and the right common carotid artery [J]. *Rev Col Bras Cir*, 2018, 45(6): e1972
- [19] Sandler ML, Sims JR, Sinclair C, et al. A novel approach to neurologic function sparing surgical management of vagal schwannomas: Continuous intraoperative nerve monitoring of the laryngeal adductor reflex[J]. *Head Neck*, 2019, 41(9): E146-e152
- [20] Sena G, Gallo G, Innaro N, et al. Total thyroidectomy vs completion thyroidectomy for thyroid nodules with indeterminate cytology/follicular proliferation: a single-centre experience[J]. *BMC Surg*, 2019, 19(1): 87-101

- [15] Toleska M, Dimitrovski A. Is Opioid-Free General Anesthesia More Superior for Postoperative Pain Versus Opioid General Anesthesia in Laparoscopic Cholecystectomy?[J]. Pril (Makedon Akad Nauk Umet Odd Med Nauki), 2019, 40(2): 81-87
- [16] Zhenqing R, Yan W, Weihua Z, et al. Efficacy of acupoint massage combined with acupoint application on arterial blood gas in patients undergoing laparoscopic cholecystectomy [J]. Pak J Pharm Sci, 2019, 32(3 Special): 1375-1380
- [17] Oshika H, Koyama Y, Usuda Y, et al. Intravenous ephedrine abolished suspected bronchoconstriction during general anesthesia in a patient undergoing beta-adrenergic blocker therapy for hypertension [J]. Saudi J Anaesth, 2019, 13(1): 63-65
- [18] Chiao F, Boretsky K. Laparoscopic Surgery in Infants Under Spinal Anesthesia Block: A Case Report of 3 Cases [J]. A A Pract, 2019, 12(5): 168-170
- [19] Sujata N, Tobin R, Tamhankar A, et al. A randomised trial to compare the increase in intracranial pressure as correlated with the optic nerve sheath diameter during propofol versus sevoflurane-maintained anesthesia in robot-assisted laparoscopic pelvic surgery [J]. J Robot Surg, 2019, 13(2): 267-273
- [20] Wang F, Zhong H, Xie X, et al. Effect of intratracheal dexmedetomidine administration on recovery from general anaesthesia after gynaecological laparoscopic surgery: a randomised double-blinded study[J]. BMJ Open, 2018, 8(4): e020614
- [21] Aditiansih D, Mochtar CA, Chandra S, et al. Comparison of Three-Quadrant Transversus Abdominis Plane Block and Continuous Epidural Block for Postoperative Analgesia After Transperitoneal Laparoscopic Nephrectomy[J]. Anesth Pain Med, 2018, 8(5): e80024
- [22] 韩智君, 丁海涛, 迪米拉, 等. 腹腔镜胆囊切除术与小切口胆囊切除术治疗胆结石的临床效果及对应激反应的影响[J]. 现代生物医学进展, 2018, 18(6): 1098-1101
- [23] Kang Y, Ni J, Wu L. Dexmedetomidine sedation combined with epidural anesthesia for laparoscopy in a patient with suspected tuberculosis: A case report[J]. Medicine (Baltimore), 2018, 97(35): e12144
- [24] Karaca Ö, Pınar HU, Duman E, et al. Laparoscopic gastrotomy under awake thoracic epidural anesthesia: A successful experience[J]. Agri, 2018, 30(3): 138-141
- [25] Erdem VM, Donmez T, Uzman S, et al. Spinal/epidural block as an alternative to general anesthesia for laparoscopic appendectomy: a prospective randomized clinical study [J]. Wideochir Inne Tech Maloinwazyjne, 2018, 13(2): 148-156
- [26] Seki H, Furumoto K, Sato M, et al. Effects of epidural anesthesia on postoperative nausea and vomiting in laparoscopic gynecological surgery: a randomized controlled trial [J]. J Anesth, 2018, 32(4): 608-615
- [27] Moawad NS, Santamaria Flores E, Le-Wendling L, et al. Total Laparoscopic Hysterectomy Under Regional Anesthesia [J]. Obstet Gynecol, 2018, 131(6): 1008-1010
- [28] Hourri K, Hamasaki S, Tsujimoto T, et al. A spinal cord infarction that occurred after laparoscopic gastrectomy performed under general anesthesia and epidural analgesia[J]. JA Clin Rep, 2018, 4(1): 6
- [29] Demiryas S, Donmez T, Erdem VM, et al. Comparison of the effects of spinal epidural and figeneral anesthesia on coagulation and fibrinolysis in laparoscopic cholecystectomy: a randomized controlled trial: VSJ Competition, 2ndplace [J]. Wideochir Inne Tech Maloinwazyjne, 2017, 12(3): 330-340
- [30] Kejriwal AK, Begum S, Krishan G, et al. aparoscopic Cholecystectomy under Segmental Thoracic Spinal Anesthesia: A Feasible Economical Alternative[J]. Anesth Essays Res, 2017, 11(3): 781-783

(上接第 1334 页)

- [21] Simo R, Nixon IJ, Vander Poorten V, et al. Surgical management of intrathoracic goitres [J]. Eur Arch Otorhinolaryngol, 2019, 276(2): 305-314
- [22] Sitges-Serra A, Gallego-Otaegui L, Fontane J, et al. Contralateral surgery in patients scheduled for total thyroidectomy with initial loss or absence of signal during neural monitoring[J]. Br J Surg, 2019, 106(4): 404-411
- [23] Siu JM, Mccarty JC, Gadkaree S, et al. Association of Vessel-Sealant Devices vs Conventional Hemostasis With Postoperative Neck Hematoma After Thyroid Operations[J]. JAMA Surg, 2019: e193146
- [24] Song E, Lee YM, Oh HS, et al. A Relook at the T Stage of Differentiated Thyroid Carcinoma with a Focus on Gross Extrathyroidal Extension[J]. Thyroid, 2019, 29(2): 202-208
- [25] Stang MT, Yip L, Wharry L, et al. Gasless Transaxillary Endoscopic Thyroidectomy with Robotic Assistance: A High-Volume Experience in North America[J]. Thyroid, 2018, 28(12): 1655-1661
- [26] Tran J, Zafereo M. Segmental tracheal resection (nine rings) and reconstruction for carcinoma showing thymus-like differentiation (CASTLE) of the thyroid[J]. Head Neck, 2019, 41(9): 3478-3481
- [27] Vaiman M, Halevy A, Cohenpour M, et al. Evaluation and management of thyroid incidentalomas detected prior to the parathyroid surgery[J]. Surg Oncol, 2018, 27(3): 508-512
- [28] Wu SY, Shen HY, Duh QY, et al. Routine Intraoperative Neuromonitoring of the Recurrent Laryngeal Nerve to Facilitate Complete Resection and Ensure Safety in Thyroid Cancer Surgery[J]. Am Surg, 2018, 84(12): 1882-1888
- [29] Xu XQ, Hong T, Zheng CJ. Schwannoma originating from the recurrent laryngeal nerve in a thyroid cancer patient: A case report and review of the literature[J]. World J Clin Cases, 2018, 6(16): 1202-1205
- [30] Zhang D, Wang T, Dionigi G, et al. Application of Carbon Nanoparticles in Endoscopic Thyroidectomy via Bilateral Areola Approach: Total Thyroidectomy Plus Central Lymph Node Dissection [J]. J Laparoendosc Adv Surg Tech A, 2019, 29(8): 1038-1041
- [31] Zong Y, Li K, Dong K, et al. The surgical choice for unilateral thyroid carcinoma in pediatrics: Lobectomy or total thyroidectomy?[J]. J Pediatr Surg, 2018, 53(12): 2449-2453