

Analysis of 30 Cases with External Auditory Canal Cholesteatoma

HOU Xiao-Feng¹, ZHU Fu-Gao¹, SUN Mei-hong², ZHANG Jun-Yao¹, ZHANG Le¹

(1 Department of Otorhinolaryngology-Head and Neck Surgery;

2 Department of Obstetrics, Affiliated Hospital of Medical College of Qingdao University, Qingdao 266003, Shandong, China)

ABSTRACT Objective: To investigate the clinical features and the optimal treatment to improve clinical diagnosis and prognosis of external auditory canal cholesteatoma (EACC). **Methods:** A retrospective study was carried out 30 cases (32 ears) with EACC were chosen. 12 ears whose lesion located in external auditory canal without bone destruction were cleared the lesion under ear endoscope; 10 ears whose lesion located in external auditory canal with extensive bone destruction or stenosis were cleared the cholesteatoma and done external auditory canal plasty by endaural incision under microscope; 10 ears whose lesion invaded into tympanic cavity or mastoid were done radical mastoidectomy by postauricular incision, if it's fitting, tympanoplasty was done in addition. **Results:** All the patients were diagnosed EACC in pathology. After surgery, the external auditory canal generous was kept, and the skin returned to normal to prevent epithelium accumulating. They had no recurrence in more than one year's following up. **Conclusions:** The combination of endoscope and microscope could remove cholesteatoma completely which will prevent residue and recurrence and improve hearing.

Key words: Cholesteatoma of external auditory canal; Mastoid; Tympanoplasty; Canal plasty

Chinese Library Classification (CLC): R739.6 **Document code:** A

Article ID: 1673-6273(2010)04-698-05

Introduction

Acquired cholesteatoma is an inflammatory mass of the petrous temporal bone. It is most commonly encountered in the middle ear cavity. External auditory canal cholesteatoma (EACC) is an uncommon form of cholesteatoma. It is rare entity with an estimated occurrence of one in 1000 new patients at otolaryngology clinics. A cholesteatoma is a cystic structure lined by keratinizing stratified squamous epithelium with associated periostitis and bone erosion. EACC is easily mixed with keratosis obturans (KO) and External ear canal cerumen. And patients may suffer a lot from hearing loss, otorrhea, ear pain, often be misdiagnosed as middle ear cholesteatomas. In this paper, 30 cases (32 ears) whose final diagnosis was EACC by clinical and pathological methods from 1994 to 2009 in our department were studied.

1 Material and Methods

1.1 Clinical data

In 30 EACC cases (32 ears), 9 cases were male and 21 were female. The patients' ages range from 4 to 75 years old (mean age, 27 years). 15 cases happened in the left ear, 13 in the right ear, and 2 in both ears. Clinical manifestations: There were hearing loss in all 32 ears; otorrhea in 19 ears, of which 13 ears were purulent otorrhea and 9 ears were bloody otorrhea; Ear pain in 18 ears; and tinnitus in 8 ears. The interval from the onset of symptoms to visiting doctor was 8 days to 20 years. None of them were affiliated

with facial palsy in their visiting.

Clinical examination: All external auditory canals of the patients were blocked with gray squamous epithelium things or gray-brown mass as cerumen. 9 of them show granulation obstructing the access of external auditory canal, skin erosion and purulent discharge, gray masslike keratinized epithelium could be seen after removing the granulation. 3 canals were occluded by cerumen in which there was white masslike squamous epithelial keratosis after removing the cerumen. 2 ears, blocked, proliferated with scar in depth of which existed cholesteatoma.

Results of pure tone threshold: 30 patients have varying degrees of hearing loss. Ossicular chain intact in 30 ears, the language frequency (500Hz, 1 kHz, 2 kHz), air conduction threshold average (41.25 ± 11.62) dB, bone conduction threshold average (17.01 ± 9.06) dB, air-bone gap average (22.99 ± 7.15) dB. 2 patients whose ossicular chains were destroyed, the language frequency (500Hz, 1kHz, 2kHz), air conduction threshold average (61.67 ± 4.08) dB, bone conduction threshold average (23.33 ± 2.58) dB, air-bone gap average (39.17 ± 3.76) dB.

Temporal bone CT scanning: 31 of the 32 ears were pneumatic mastoid, while 1 ear was diploic mastoid. Bone segment of external auditory canal was filled with soft tissue shadow in all the patients and bone wall expanded to vary direction in different degree by erosion, the typical ones were changed into the shape of flask whose mouth is small as bottom broad, tympanic shield plate showed dilatancy bone defection from outer to the inner side, and tympanic membrane was always be pushed attached to the promontory. CT performance refers to H o l t stage^[1], the development of EACC is divided into three stages: I, Bony wall of the external auditory canal cholesteatoma was oppressive limitations caused by more superficial pits; II, the formation of

Author introduction: HOU Xiao-feng, (1984-), female, master Mainly engaged in basic and clinical research of Otolaryngology, TEL:13675323690, E-mail:houxiaofeng2008@126.com
△Corresponding author: ZHU Fu-Gao, E-mail:zhufugao@yahoo.com.cn
(Received: 2010-11-05 Accepted: 2010-11-30)

cholesteatoma pouch, limited to the external auditory canal, and bone wall erosion; Ⅲ, destruction of the external auditory canal cholesteatoma invaded the attic, mastoid In this study, 12 ears were in stage I (Figure 1); 10 ears in stage II (Figure 2); 10 ears in stage III (Figure 3).

In surgery: All cases of bony external auditory canal expansion, full of cholesteatoma. There were 6 ears, for which the lesion destroyed the posterior wall of external auditory canal, and the violation of the mastoid cavity. There were 2 ears, for which the tympanic shield plates are destroyed and invaded lesions attic. There were 2 ears, for which the tympanic plate and external auditory canal posterior wall of shields are destroyed; the lesion invaded the mastoid sinus tympani drums. 28 eardrums intact, but the tympanic membrane retraction cholesteatoma oppression. 2 membrana flaccida were Perforating. 2 eardrums were completely destroyed. ossicular chain of 30 ears were integral and in good activity. 2 ears malleus, incus, stapes damage absorption.

Pathology: All the pathological diagnosis after surgery were cholesteatoma.

1.2 Treatment

Different management should be chosen according to the different clinical stage.

1.2.1 Lesions cleared in the ear endoscopy (12 ears) 10 stage I ears and 2 stage II ears were performed. There were less bone destruction and more lenient external auditory canal cartilage segment in all the ears undergoing ear endoscopy. By 00 ear endoscope through the external ear canal, the cholesteatoma were pried along the canal wall gently with detacher, to separate it from the bone wall and removed or draw it off; During the whole operation it was necessary to avoid damaging the tympanic membrane. If it is accompanied with granulation proliferation, granulation proliferation should be cut off with polyp forceps. The destruction of bone walls were detected by 300 ears endoscope and the residual cholesteatoma epithelium, granulation tissue and pus were cleaned up, avoiding damage the external auditory canal skin. After the operation, Levofloxacin Hydrochloride + dexamethasone gauze were used to fix into the canal, and dressing was changed once one day, last 3 days. Then the ear canal was washed with 3% hydrogen peroxide and the compound chloramphenicol ear drops for 1 week. Patients should be periodically reviewed.

1.2.2 Lesions Cleared under the microscope by the endaural incision (10 ears) 2 stage I ears and 8 stage II ears. All their lesions were confined to the external ear canal and cartilage segment of the external auditory canal are narrowed. The lesions were cleared under microscope by incision in the ear, and then external ear canal was polished as enlargement. That was, removing the relatively narrowed part of the bony external auditory canal, thus expanding the bony external auditory canal homogeneously. For

the patients with aural atresia, atresia open were usually cut before giving above treatment. For patients with large skin defects. Temporal fascia was taken as graft to promote wound healing. Then, filling gelatin sponge and iodoform gauze into the canal. After 2 weeks, we took out the wadding, dressing and reviewing regularly.

1.2.3 Lesions Cleared under the microscope by the postauricular incision (10 ears) they were all stage III ears in which the cholesteatoma invaded into attic or the mastoid sinus drum. Post auricular incision was taken and the lesion was cleared under microscope. For 6 ears with mastoid disease, the mastoid cavity lesions were clear, and then they were closed with autologous temporal fascia mastoid cavity. 2 ear lesions invaded the attic, tympanic membrane perforation of the Ministry of relaxation, the lesions cleared with autologous temporalis fascia patch perforation. For 2 ears, the lesion invaded tympanic cavity, antrum tympanicum and the mastoid sinus. Malleus, incus, stapes bone destruction, radical mastoidectomy remove lesions. Excluding these patients, the remaining cases were made canal plasty. Autologous temporal fascia was used to repaired the eardrum perforation and the surgical cavity was packed with gelatin sponge and iodoform gauze. 2 weeks later, the iodoform gauze were removed and dressed regularly. 6 to 8 weeks later, the cavity healed and coverage with epithelium. Reviewing regularly.

2 Results

All 30 patients (32 ears) were cured and followed up for more than 1 year, there was no cholesteatoma recurrence. 12 ears in stage I, 10 ears in stage II, and 6 ears in stage III, these patients were done Simple cholesteatoma dissection. After operation their hearing returned to normal. 2 ears were done tympanic cholesteatoma dissection and repaired the patients (those intact ossicular chains). After surgery, they returned to normal hearing. Air conduction threshold average (21.59 ± 3.74) dB, compared with preoperative, $t = 14.25$, $P < 0.01$ statistical significance. Bone conduction threshold average (18.26 ± 4.37) dB, compared with preoperative, $t = 1.25$, $P > 0.05$, the difference was not statistically significant. Air-bone gap average was (3.33 ± 3.14) dB. Compared with preoperative, $t = 20.1$, $P < 0.01$ significant difference; 2 ears who do radical mastoidectomy (ossicular chain breaker), after operation, air conduction threshold average (60.83 ± 5.85) dB, compared with preoperative, $t = 0.54$, $P > 0.05$, the difference was not statistically significant. Bone conduction threshold average (23.33 ± 2.580) dB, compared with preoperative, $t = 0$, $P > 0.05$, the difference was not statistically significant. Air-bone gap average was (37.50 ± 4.18) dB, compared with preoperative, $t = 1.58$, $P > 0.05$, the difference was not statistically significant.

3 Discussion

External auditory canal Cholesteatoma is an external ear canal disease that originate from external ear canal epithelium clumps containing cholesterol crystals, but the exact etiology is unclear. In EACC, lateral epithelium desquamation is affected. Keratin debris is blocked, causing local erosion and bone lysis, which can be severe [2,3]. Commonly, most onset of EACC was in nature, and few get the history of surgery, trauma or inflammatory, which can destroy the integrity and physiological function, leading to cell proliferation of stratum germinativum and apoptosis barrier of keratinocyte which will provoke proliferation, abscission and accumulation of keratinized squamous epithelium. Meanwhile, the fallen epithelium will exclude difficult if there exists factors as

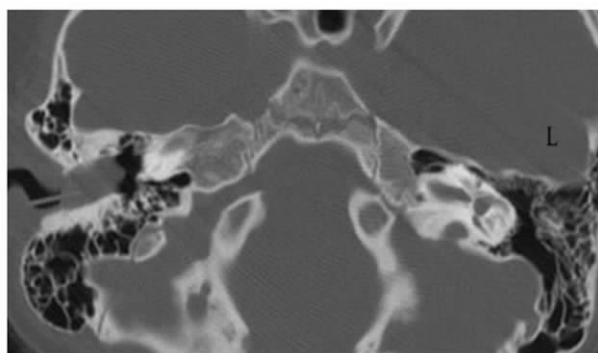


Fig 1 Both sides of the mastoid processes are gasification type. The right ear canal with soft tissue density and slight expansion of the external auditory canal bone.

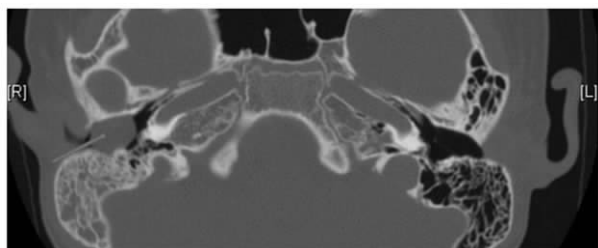


Fig 2 Both sides of the mastoid processes are gasification type. Right side of the bony external auditory canal can be seen within the soft tissue density, local bone destruction, the formation of the capsular bag, expanding external auditory canal bone, mastoid air room soft tissue density, and room separated without damage.

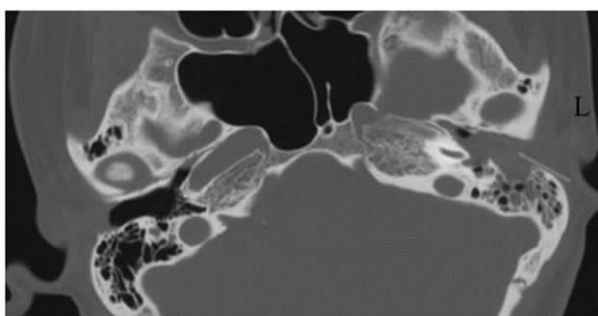


Figure3 Both sides of the mastoid processes are gasification type. The left tympanic cavity, mastoid and ear canal filled with soft tissue density, the left mastoid air cell bone is destroyed, expanding external auditory canal bone

self-cleaning barrier, stenosis of external ear canal, or congenital aural atresia, and so on.

At present, the normal metabolism of ear canal skin is disturbed, the over proliferated and keratotic cell falls and accumulate in the external ear canal, the inner part of the accumulated epithelium become hypoxia, corrupt and decompose, resulting in cholesterol crystals into cholesteatoma. Meanwhile, granulation tissue produces epidermal growth factor and lyocollagenase which corrode the bone wall of external auditory canal and grow invasively to dilate the external auditory canal wall to the surrounding, which may corrode the structure of middle ear leading to widespread bone destruction [4,5]. However, the mechanism of the bony destruction in cholesteatoma remains controversial. Most theories of the bony destruction or resorption in cholesteatoma with chronic otitis media involve pressure necrosis, osteolysis, or contact between the inflammatory granulation tissue and bone, which cause a series of enzymatic bony destructions [6,7].

Local inflammation, in which IL-1, TNF- α and GM-CSF (Granulocyte-macrophage colony stimulating) factor are the main factors leading to dissolution and absorption of sclerotin is the primary cause of bone destruction caused by EACC. Bujia J [8] proved that IL-1 originating from keratinocyte plays an important role in the high proliferation of keratinized epithelial and bone destruction by gene express detection techniques.

In the early stage, patients with EACC may feel blocked, as it developed, it may present with hearing loss, tinnitus, smelly or bloody purulent secretion. In severe patients, it may accompany with ear-ache, headache, or facial palsy, and so on. Its main clinical features are intermittent or persistent ear pus, dull pain, choking feeling, hearing loss and bony external auditory canal expansion.

In clinical, it needs to distinguish from middle ear cholesteatomas, keratosis obturans (KO). Both EACC and middle ear cholesteatomas get the same tissue source, which show same biological behavior as over proliferation of squamous epithelium, accumulation of fallen keratotic epithelium and erosion of sclerotin. But, there exists difference in etiology, development, and treatment, so, it was necessary to differentiate them. The incidence rate of EACC is lower when the cholesteatoma increases; it not only produces compressive bone absorption, but also dilates the external auditory canal by the proteinase in cholesteatoma. It may destroy the anterior and inferior wall of the canal besides the superior posterior mastoid and atticus. Embolization of the external auditory canal keratosis often involved both ears, no bone damage, mostly acute pain, often accompanied by sinusitis and bronchiectasis, only non-surgical method to clear the lesions [9-10]. External auditory canal is characterized by bone erosion.

The destructive points of EACC are mainly located in the ex-

ternal auditory canal, when it invades into middle ear, it manifests as the erosion of tympanic shield plate from external auditory canal. In pneumatic and diploetic mastoid patients, the tympanic membrane is usually pushed onto the promontory. In patient with sclerotic mastoid, the damage of middle ear cholesteatomas is often from the attic to tympanic shield plate, and the horizontal segment of facial nerve bony tube and cone curved pipe segment of bone is relatively in high risk of involvement. And in EACC, violations of external auditory canal vertical segment of the facial nerve and chorda tympani tubules more easily involved^[11].

Management of the patients is notably different during its clinical stages. High-resolution computed tomography can be used to detail the middle ear structures of the facial nerve and semicircular canals and the tegmen tympani^[12]. According to Holt stage, it was believed that patients in stage I and those in II but not associated with cartilage canal stenosis could be managed under endoscopic surgery, during which keeping the tympanic membrane integrity; patients in stage II associated with the external auditory canal cartilage segment stenosis, the cholesteatoma plug in the external ear canal to form a capsular, and corrode the bone wall. The external auditory canal would be in the shape of flask after removing the cholesteatoma which is not good for drainage. It was needed to do external auditory canal plasty to promote the discharge of secretion to prevent the recurrence of cholesteatoma; Patients in Stage III, the cholesteatoma invaded into the attic, sinus and mastoid drum, should be done mastoidotomy under microscope in anesthesia, removing the foci. If it was fitted, tympanoplasty would be done, which not only clearing the lesions but also improving the hearing.

In the healing process of EACC, it requires remove the cholesteatoma thoroughly in principle. However, there is blind area in surgery because the lesions could not be detected directly due to the concealed lesion in patients with EACC whose auditory canal cartilage segment expanded and bone segment narrowed. And the lesion not only located in the external auditory canal, but also invaded into tympanic cavity and mastoid. The surgery may be done under microscope or direct vision, in which the visual fields were small and vague and it may hurt tympanic membrane, facial nerve, and lesions usually were left over. The tympanic and mastoid segments were mostly vulnerable to injury during otologic surgery^[13,14]. Although facial nerve injury was an iatrogenic complication, incidence had declined markedly, from 15% to 1%, because of improvements in surgical microscopy and with the use of motorized drills^[15]. Ear endoscope could provide good lighting and high-resolution images, and the angle and distance of observation can be adjusted. It's easy to round the physiological curvature in different angle so as to get close the lesion for detailed observation. It made up for the shortcomings of conven-

tional microscope, and also reduced unnecessary surgical incision. But there still were drawbacks, such as operate with only one hand, the image was planar, and the endoscope was easily contaminated with blood, thus increased the difficulty of surgery. Moreover, it's a defective operation to remove the ear bone endoscope with an electric drill under endoscope. Therefore, some patients need further exposure of the operative field can't remove the lesion under endoscopic ear completely.

Surgical microscope could show the field clearly, which provides reliable three-dimensional stereoscopic images, and the eyepiece was far from the surgical operating area, avoiding being contaminated. And we can operate in two hands which reduces the difficulty of surgical procedure too. For patients who need radical mastoidectomy line operation was necessary. However, because of its cost, narrowed operative field and observation only in lens axis, its promotion and application are limited. Thus, both endoscopic and microscopic ear surgery get their advantages and disadvantages in otologic surgery. In clinical work, the combination of endoscopy and microscopy in clearing cholesteatoma will remove the cholesteatoma clearly and prevent recurrence, and we can see the lesion directly to make sure the degree. If it's feasible for tympanoplasty, we will do it to improve the hearing and the life quality of patients.

References

- [1] Holt JJ. Ear canal cholesteatoma [J]. *Laryngoscope*, 1992, 102: 608-613
- [2] Garin P, Degols JC, Delos M. External Auditory Canal Cholesteatoma [J]. *Otolaryngol-Head-Neck-Surg*, 1997, 123(1): 62-5
- [3] Segal J, Ostfeld E, Hermon R, et al. Primary Cholesteatoma of the External Auditory Meatus [J]. *Harefuah*, 1991, 120(12): 719-20
- [4] Sun HR. Diagnosis and treatment of external auditory canal cholesteatomas [J]. *Chinese Journal of Otolaryngology*, 2006, 4(3): 217-219
- [5] Heilbrun ME, Salzman KL, Glastonbury CM, et al. External auditory canal cholesteatoma: clinical and imaging spectrum [J]. *Am J Neuroradiol*, 2003, 24:751-756
- [6] Selesnick SH, Lynn-Macrae AG. The incidence of facial nerve dehiscence at surgery for cholesteatoma [J]. *Otol Neurotol*, 2001, 22: 129-132
- [7] Uno Y, Saito R. Bone resorption in human cholesteatoma: morphological study with scanning electron microscopy [J]. *Ann Otol Rhinol Laryngol*, 1995, 104:463-468
- [8] Bujia J, Holly A, Candela F A, et al. Immunobiological peculiarities of cholesteatoma in children: Quantification of epithelia proliferation by MIB1 [J]. *Laryngoscope*, 1996, 106(7):865-868
- [9] Anthony PF, Anthony WP. Surgical Treatment of external auditory canal cholesteatoma [J]. *Laryngoscope*, 1982, 92(1):70
- [10] Holt JJ. Ear canal cholesteatoma [J]. *Laryngoscope*, 1992, 102(6): 608-613
- [11] Sun HR, Zhu LY, Wang L, et al. Clinical characteristics of external

auditory canal cholesteatoma. [J]. Clinical Journal of Otorhinolaryngology, 2006, 20(10):471-472

[12] Blevins NH, Carter BL. Routine preoperative imaging in chronic ear surgery [J]. Am J Otol, 1998,19:527-535 [13]Bayazit YA, Ozer E, Kanlikama M. Gross dehiscence of the bone covering the facial nerve in the light of otological surgery [J]. J Laryngol Otol, 2002, 116: 800-803

[14] Green JD Jr, Shelton C, Brackmann DE. Iatrogenic facial nerve injury during otologic surgery [J]. Laryngoscope. 1994, 104:922-926

[15] Nilssen EL, Wormald PJ. Facial nerve palsy in mastoid surgery [J]. J Laryngol Otol, 1997, 111:113-116

外耳道胆脂瘤 30 例临床分析

侯晓丰¹ 朱富高^{1△} 孙美红² 张俊瑶¹ 张 乐¹

(青岛大学医学院附属医院 1 耳鼻咽喉 - 头颈外科;2 产科 山东 青岛 266003)

摘要 **目的:**探讨外耳道胆脂瘤的临床特征和最佳治疗方法,提高临床诊治水平。**方法:**回顾性分析 30 例(32 耳)外耳道胆脂瘤患者的临床资料。12 耳病变局限于外耳道无明显骨质破坏,经耳内窥镜下行胆脂瘤清除术;10 耳病变局限于外耳道,但有较广泛的骨质破坏或有外耳道口狭窄者,经耳内切口显微镜下清除病变并加行外耳道成形术;10 耳病变侵及鼓室或乳突,在显微镜下经耳后切口行乳突根治术。有条件者行乳突根治术加鼓室成形术。**结果:**本组病例所有患者术后病理均为胆脂瘤。术后外耳道口保持宽大,外耳道皮肤恢复正常,不产生上皮堆积。随访 1 年以上胆脂瘤无复发。**结论:**耳内镜与显微镜配合应用可彻底清除胆脂瘤,防止胆脂瘤残留和复发,并能提高听力。

关键词:外耳道胆脂瘤;乳突;鼓室成形术;外耳道成形术

中图分类号:R739.6 **文献标识码:**A **文章编号:**1673-6273(2011)04-698-05

作者简介:侯晓丰(1984-),女,硕士研究生,主要从事耳鼻咽喉基础及临床研究。TEL:13675323690,E-mail:houxiaofeng2008@126.co
△通讯作者:朱富高(1961-),男,教授,硕士研究生导师,主要从事耳科学基础及临床研究。E-mail: zhufugao@yahoo.com.cn
(收稿日期:2010-11-05 接受日期:2010-11-30)